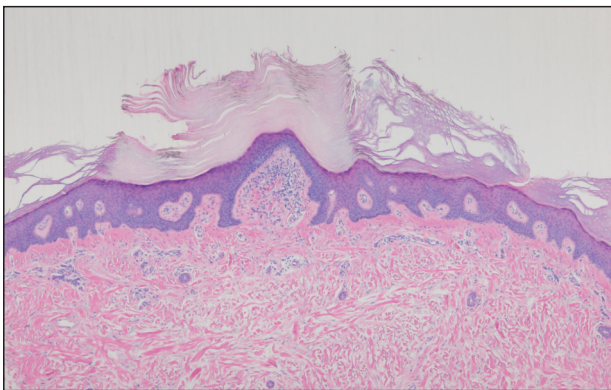


Spiky Papules on the Dorsal Feet

Dema T. Alniemi, MD; Laura Greene, MD; Melanie Bui, MD, PhD

Eligible for 1 MOC SA Credit From the ABD

This Dermatopathology Diagnosis in our print edition is eligible for 1 self-assessment credit for Maintenance of Certification from the American Board of Dermatology (ABD). After completing this activity, diplomates can visit the ABD website (<http://www.abderm.org>) to self-report the credits under the activity title "Cutis Dermatopathology Diagnosis." You may report the credit after each activity is completed or after accumulating multiple credits.



H&E, original magnification $\times 4$.

A 54-year-old man who was otherwise healthy presented with asymptomatic, discrete, rough, red-brown, hyperkeratotic papules on the dorsal aspects of the feet of several years' duration. The lesions spared the soles of the feet and hands. A diagnosis of eczema previously was made by his general practitioner, and he was using moisturizer. No prescription treatments were pursued, and no other rashes or lesions were noted on physical examination. A punch biopsy of a spiky papule was performed.

THE BEST DIAGNOSIS IS:

- acrokeratosis verruciformis of Hopf
- hyperkeratosis lenticularis perstans (Flegel disease)
- perforating granuloma annulare
- punctate porokeratosis
- stucco keratosis

PLEASE TURN TO **PAGE 124** FOR THE DIAGNOSIS

From the Division of Dermatology, University of Vermont Medical Center, Burlington. Dr. Greene also is from the Department of Pathology. The authors report no conflict of interest.

Correspondence: Dema T. Alniemi, MD, University of Vermont, Division of Dermatology, 111 Colchester Ave, Burlington, VT 05401 (dema.alniemi@uvmhealth.org).

THE DIAGNOSIS:

Hyperkeratosis Lenticularis Perstans (Flegel Disease)

Hyperkeratosis lenticularis perstans, also known as Flegel disease, is a rare dermatosis first described by Flegel¹ in 1958. This benign disorder is characterized by multiple asymptomatic 1- to 5-mm keratotic papules in a symmetric distribution favoring the dorsal aspects of the feet and distal extremities in adults. An autosomal-dominant inheritance pattern has been postulated, though many cases sporadically occur.² The characteristic spiky papules typically appear during mid to late adulthood and tend to persist. Treatment options are lacking, with reports of partial or no response to topical calcipotriol, topical 5-fluorouracil, cryotherapy, and topical and oral retinoids.^{3,4}

The histopathology of hyperkeratosis lenticularis perstans is distinct, showing a central discrete area of orthohyperkeratosis with patchy parakeratosis flanked by a normal stratum corneum. The underlying epidermis typically shows effacement of the rete ridge pattern with

subtle basal zone vacuolization and rare necrotic keratinocytes with an underlying lichenoid infiltrate within the papillary dermis comprised of lymphomononuclear cells.

In contrast, punctate porokeratosis clinically tends to involve the palms and soles, though the arms and legs also may be involved. This entity tends to occur during adolescence. A raised hyperkeratotic papule clinically is present. Histopathologically, the epidermis has a cup-shaped depression filled with hyperkeratosis and a column of parakeratosis (coronoid lamellae) (Figure 1).

Acrokeratosis verruciformis of Hopf clinically appears on the dorsal aspects of the hands and feet as small warty papules in association with Darier disease. It typically presents during early childhood. Histopathology shows tiered hyperkeratosis, papillomatosis, and acanthosis (Figure 2).

Perforating granuloma annulare presents on the dorsal aspects of the hands and fingers as scaly papules

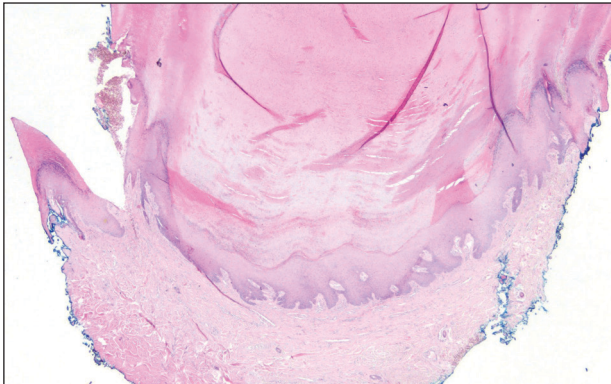


FIGURE 1. Punctate porokeratosis. Hyperkeratotic papule with parakeratosis (H&E, original magnification $\times 20$).

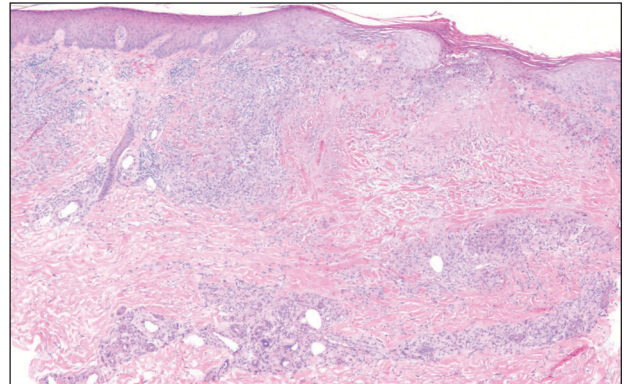


FIGURE 3. Perforating granuloma annulare. Transepidermal elimination of degenerated collagen (H&E, original magnification $\times 40$).

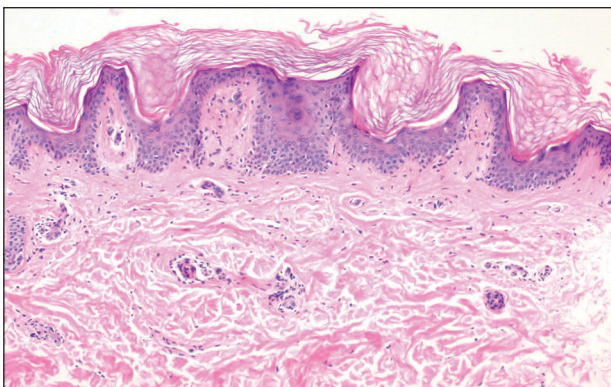


FIGURE 2. Acrokeratosis verruciformis of Hopf. Hyperkeratosis, papillomatosis, and acanthosis (H&E, original magnification $\times 100$).

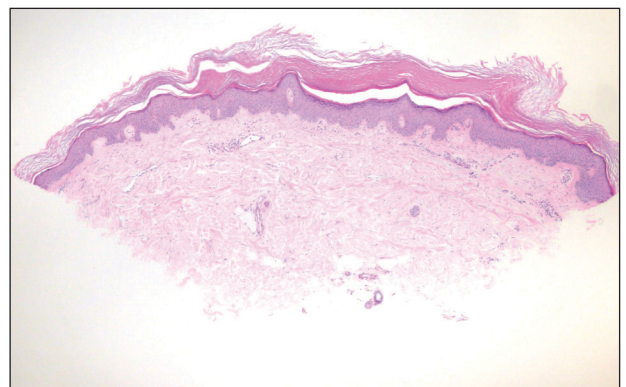


FIGURE 4. Stucco keratosis. Retention hyperkeratosis and regular acanthosis with a "string sign" (H&E, original magnification $\times 40$).

with either central umbilication or keratotic plugs. Histopathology shows transepidermal elimination of degenerated collagen (Figure 3).

Stucco keratoses present on the dorsal aspects of the feet and ankles but are waxy smooth papules as opposed to hyperkeratotic spiky papules. Histologically, they are characterized by retention hyperkeratosis with lack of parakeratosis and regular acanthosis with a “string sign” indicating that the lesion extends to a uniform depth. (Figure 4).

REFERENCES

1. Flegel H. Hyperkeratosis lenticularis perstans. *Hautarzt*. 1958;9:363-364.
2. Ando K, Hattori H, Yamauchi Y. Histopathological differences between early and old lesions of hyperkeratosis lenticularis perstans (Flegel's disease). *Am J Dermatopathol*. 2006;28:122-126.
3. Langer K, Zonzits E, Konrad K. Hyperkeratosis lenticularis perstans (Flegel's disease). ultrastructural study of lesional and perilesional skin and therapeutic trial of topical tretinoin versus 5-fluorouracil. *J Am Acad Dermatol*. 1992;27:812-816.
4. Blaheta HJ, Metzler G, Rassner G, et al. Hyperkeratosis lenticularis perstans (Flegel's disease)—lack of response to treatment with tacalcitol and calcipotriol. *Dermatology*. 2001;202:255-258.